



## Umbilical Vein Catheterization

### Author Disclosure

Drs Moeckel, Cresalia, and Vachharajani have disclosed no financial relationships relevant to this article. This commentary does not contain a discussion of an unapproved/investigative use of a commercial product/device.

Douglas Moeckel, MD,\* Nicole Cresalia, MD,<sup>†</sup>  
Akshaya Vachharajani, MD<sup>‡</sup>

Please watch the video below depicting resistance to the passage of an umbilical venous catheter. Think first, then answer the question below.

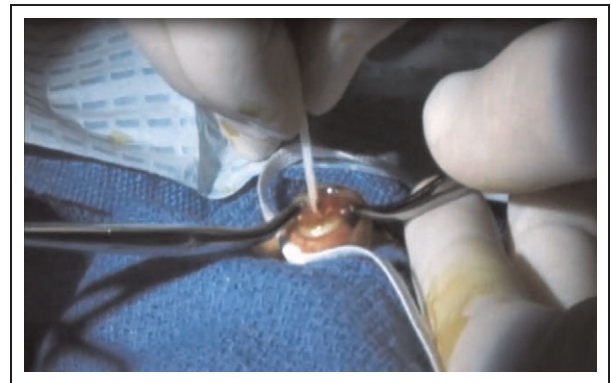


Figure. Click here to view the video.  
(Reproduced with permission of Akshaya Vachharajani, MD, and The Saigh Foundation Pediatric Simulation Center, St. Louis Children's Hospital & Washington University School of Medicine. Copyright 2012.)

How long can an umbilical venous catheter be used without risk of blood stream infection?

- a) 1 week
- b) 5 days
- c) 4 weeks
- d) 14 days
- e) 10 days

### Abbreviations

**CDC:** Centers for Disease Control and Prevention  
**CVC:** central venous catheter  
**DV:** ductus venosus  
**UVC:** umbilical venous catheter

\*Clinical Fellow in Neonatal-Perinatal Medicine, Washington University School of Medicine and St. Louis Children's Hospital, St. Louis, MO.

<sup>†</sup>Pediatric Resident, St. Louis Children's Hospital, St. Louis, MO.

<sup>‡</sup>Associate Professor of Pediatrics, Division of Neonatal-Perinatal Medicine, Washington University School of Medicine and Children's Hospital, St. Louis, MO.

## Critique and Discussion

Time out is not recorded on the video to protect the identity of the neonate.

The video depicts the resistance to the passage of the catheter. A momentary resistance was frequently but not always felt as the catheter tip entered the ductus venosus (DV) in a study by Dunn. (1) A study revealed that all 50 (100%) of the neonates examined by ultrasound had a patent DV on day 1. (2) Only 33 (66%) of these neonates had a patent DV at 5 days of age. The resistance felt is most probably due to the anatomy and not DV closure. This is because the DV connects the umbilical vein and the hepatic veins at approximately 90° angle. (1)

The video demonstrates one of the methods to successfully negotiate an umbilical venous catheter (UVC) across the DV. It was successful on this occasion (after multiple attempts), but success is not guaranteed. Mandel et al (3) describe a double catheter technique that has a 50% success. Dunn (1) describes a possibility of the catheter traversing the DV in 86% of the cases and the foramen ovale in 70% of the cases.

Various formulas are used to determine the length of catheter to be inserted in the umbilical vein. The formula used in the video was described by Shukla et al. (4) Estimates of the length of the catheter to be inserted are described by Dunn (1) in his postmortem study on neonates. The study attempts to correlate the length of catheter (required to be passed up the umbilical vessels to reach various anatomical sites within the body) to the external measurements of 50 infants dying during the perinatal period. The catheter could be passed a greater distance if it traversed the DV. A newer formula is described by and compared with the formula suggested by Shukla et al. (5)

There is no international consensus on position of the tips of the UVCs on radiographs. Plain radiographs, echocardiography, and ultrasound scans are utilized to confirm the successful catheterization and locate the tip of the UVC. (6)(7) Multiple publications describe the abnormal UVC tip positioning detected radiologically. (8)(9)

Pericardial effusion and cardiac tamponade are described with intracardiac location of the tip of the UVC. The Food and Drug Administration Patient Safety News describes cardiac perforation and tamponade as a “deadly duo of central venous catheters.” (10) Of all deaths related to central venous catheters (CVCs), 20% were in neonates. (11) Cardiac perforation and tamponade accounted for 43% of all deaths related to CVC. Tamponade was reported more frequently in neonates although cardiac perforation was reported equally in both adults and neonates.

Mechanisms of tamponade include leakage of hyperalimentation fluid into the pericardial sac or by direct perforation of the heart by the catheter (12); erosion of the atrial wall and eventual perforation of the wall (13); and damage to the endocardium with each atrial contraction. (14) A retrospective case study revealed autopsy findings in 18 cases of pericardial effusion related to CVC. (15) Myocardial necrosis and/or thrombus formation at the site of the CVC was noted in 42% of the cases, perforation without myocardial necrosis and/or thrombus formation was noted in 47% of the cases, and in one case no perforation was detected. (15) The authors speculate that the mechanisms for pericardial effusion related to CVC range from frank perforation of the myocardium that seals spontaneously to adhesion of the CVC tip to the myocardium with diffusion into the pericardial space. Complications of the umbilical venous catheterization such as infection and venous thrombosis are described. (16)

Multiple interventions have been recommended to prevent central line associated blood stream infections. Limiting central line access for blood draws or injecting medications, enforcing “scrub the hub” before accessing the central line, removing the UVC as soon as possible, and replacing UVCs with peripherally inserted central catheters are some of the suggested interventions. The Centers for Disease Control and Prevention (CDC) guidelines recommend removal of UVCs as soon as possible when no longer needed but endorse the use for up to 14 days if managed aseptically. (17) Butler-O’Hara et al performed a randomized controlled trial that revealed similar infection and complication rates between infants managed with a UVC in place for up to 28 days compared with infants managed with a UVC replaced by a percutaneous CVC after 7 to 10 days. (18) This contradicts the CDC guidelines.

A study comparing umbilical venous and intra-osseous line placement during simulated neonatal resuscitation revealed that the intra-osseous line was placed in less time than the UVC. (19)

Correct Response: Answer d. The CDC guidelines for the prevention of intravascular catheter related infections recommend that UVCs should be removed as soon as possible when no longer needed but can be used up to 14 days if managed aseptically.

We thank Bryan Camp (Media Services at St. Louis Children’s Hospital, St. Louis, MO) for the production and editing of the video.

## References

1. Dunn PM. Localization of the umbilical catheter by post-mortem measurement. *Arch Dis Child*. 1966;41(215):69–75

2. Fugelseth D, Lindemann R, Liestøl K, Kiserud T, Langslet A. Ultrasonographic study of ductus venosus in healthy neonates. *Arch Dis Child Fetal Neonatal Ed.* 1997;77(2):F131–F134
3. Mandel D, Mimouni FB, Littner Y, Dollberg S. Double catheter technique for misdirected umbilical vein catheter. *J Pediatr.* 2001; 139(4):591–592
4. Shukla H, Ferrara A. Rapid estimation of insertional length of umbilical catheters in newborns. *Am J Dis Child.* 1986;140(8): 786–788
5. Verheij GH, Te Pas AB, Smits-Wintjens VE, Srámek A, Walther FJ, Lopriore E. Revised formula to determine the insertion length of umbilical vein catheters [published online ahead of print March 16, 2013]. *Eur J Pediatr.* 2013
6. Ades A, Sable C, Cummings S, Cross R, Markle B, Martin G. Echocardiographic evaluation of umbilical venous catheter placement. *J Perinatol.* 2003;23(1):24–28
7. Greenberg M, Movahed H, Peterson B, Bejar R. Placement of umbilical venous catheters with use of bedside real-time ultrasonography. *J Pediatr.* 1995;126(4):633–635
8. Weber AL, DeLuca S, Shannon DC. Normal and abnormal position of the umbilical artery and venous catheter on the roentgenogram and review of complications. *Am J Roentgenol Radium Ther Nucl Med.* 1974;120(2):361–367
9. Schlesinger AE, Braverman RM, DiPietro MA. Pictorial essay. Neonates and umbilical venous catheters: normal appearance, anomalous positions, complications, and potential aid to diagnosis. *AJR Am J Roentgenol.* 2003;180(4):1147–1153
10. Food and Drug Administration. The Food and Drug Administration Patient Safety News Show #1, February 2002. Available at: <http://www.accessdata.fda.gov/scripts/cdrh/cfdocs/psn/printer.cfm?id=119>. Accessed June 20, 2013
11. Yoder D. Cardiac perforation and tamponade: the deadly duo of central venous catheters. *Int J Trauma Nurs.* 2001;7(3): 108–112
12. Wirrell EC, Pelausa EO, Allen AC, Stinson DA, Hanna BD. Massive pericardial effusion as a cause for sudden deterioration of a very low birthweight infant. *Am J Perinatol.* 1993;10(6):419–423
13. Chabanier A, Dany F, Brutus P, Vergnoux H. Iatrogenic cardiac tamponade after central venous catheter. *Clin Cardiol.* 1988;11(2):91–99
14. Agarwal KC, Khan MA, Falla A, Amato JJ. Cardiac perforation from central venous catheters: survival after cardiac tamponade in an infant. *Pediatrics.* 1984;73(3):333–338
15. Nowlen TT, Rosenthal GL, Johnson GL, Tom DJ, Vargo TA. Pericardial effusion and tamponade in infants with central catheters. *Pediatrics.* 2002;110(1 pt 1):137–142
16. Anderson J, Leonard D, Braner DA, Lai S, Tegtmeier K. Videos in clinical medicine. Umbilical vascular catheterization. *N Engl J Med.* 2008;359(15):e18 10.1056/NEJMvcm0800666
17. O’Grady N, Alexander M, Burns L, et al. Guidelines for the Prevention of Intravascular Catheter-Related Infections, 2011. Available at: <http://www.cdc.gov/hicpac/pdf/guidelines/bsi-guidelines-2011.pdf>. Accessed June 20, 2013
18. Butler-O’Hara M, Buzzard CJ, Reubens L, McDermott MP, DiGrazio W, D’Angio CT. A randomized trial comparing long-term and short-term use of umbilical venous catheters in premature infants with birth weights of less than 1251 grams. *Pediatrics.* 2006; 118(1):e25–e35
19. Rajani AK, Chitkara R, Oehlert J, Halamek LP. Comparison of umbilical venous and intraosseous access during simulated neonatal resuscitation. *Pediatrics.* 2011;128(4):e954–e958 10.1542/peds.2011-0657

## Umbilical Vein Catheterization

Douglas Moeckel, Nicole Cresalia and Akshaya Vachharajani

*NeoReviews* 2013;14:e416

DOI: 10.1542/neo.14-8-e416

### Updated Information & Services

including high resolution figures, can be found at:  
<http://neoreviews.aappublications.org/content/14/8/e416>

### References

This article cites 16 articles, 6 of which you can access for free at:  
<http://neoreviews.aappublications.org/content/14/8/e416.full#ref-list-1>

### Subspecialty Collections

This article, along with others on similar topics, appears in the following collection(s):  
**Pediatric Drug Labeling Update**  
[http://classic.neoreviews.aappublications.org/cgi/collection/pediatric\\_drug\\_labeling\\_update](http://classic.neoreviews.aappublications.org/cgi/collection/pediatric_drug_labeling_update)

### Permissions & Licensing

Information about reproducing this article in parts (figures, tables) or in its entirety can be found online at:  
<https://shop.aap.org/licensing-permissions/>

### Reprints

Information about ordering reprints can be found online:  
<http://classic.neoreviews.aappublications.org/content/reprints>



**Umbilical Vein Catheterization**

Douglas Moeckel, Nicole Cresalia and Akshaya Vachharajani  
*NeoReviews* 2013;14:e416  
DOI: 10.1542/neo.14-8-e416

The online version of this article, along with updated information and services, is located on the World Wide Web at:  
<http://neoreviews.aappublications.org/content/14/8/e416>

Neoreviews is the official journal of the American Academy of Pediatrics. A monthly publication, it has been published continuously since 2000. Neoreviews is owned, published, and trademarked by the American Academy of Pediatrics, 141 Northwest Point Boulevard, Elk Grove Village, Illinois, 60007. Copyright © 2013 by the American Academy of Pediatrics. All rights reserved. Online ISSN: 1526-9906.

**American Academy of Pediatrics**

DEDICATED TO THE HEALTH OF ALL CHILDREN<sup>®</sup>

